

Clinical Evaluation of Lesion Sterilisation and Tissue Repair Therapy using Bioceramic in Deciduous Molars with Chronic Periapical Periodontitis and Pulp Necrosis: A Randomised Controlled Trial

JIN SUN¹, JIAHUI HE², WEI LUO³, MIN WU⁴, YUN LIU⁵

ABSTRACT

Introduction: Lesion Sterilisation and Tissue Repair Therapy (LSTR) has proven to be as effective as Root Canal Therapy (RCT) for treating deciduous molars with chronic periapical periodontitis and pulp necrosis. Given the routine use of a three-antibiotic mixture, it is important to investigate a more effective medication that offers antibacterial properties, good biocompatibility, and stable chemical characteristics.

Aim: To evaluate the efficacy of LSTR with bioceramic (LSTR-bioceramic) in deciduous molars with chronic periapical periodontitis and pulp necrosis.

Materials and Methods: A randomised controlled trial was conducted in the Stomatological Healthcare Centre, Shenzhen Maternity and Child Healthcare Hospital affiliated to Southern Medical University, Shenzhen, Guangdong, China, from January 2022 to December 2023. The study included 88 children aged 3-8 years, all diagnosed with chronic periapical periodontitis and pulp necrosis. These cases were treated according to the

study protocol, with 44 subjects receiving RCT and the other half receiving LSTR therapy. The subjects were followed-up clinically and radiologically at six and 12 months. The results were rigorously analysed using a Z-test, with a significance level established at 0.05.

Results: At six months, the clinical success rates of LSTR-bioceramic and RCT were 37 (84.09%) and 41 (93.18%), respectively; the radiological success of them were 39 (88.64%) and 37 (84.09%). And at 12 months, the clinical success rates of LSTR-bioceramic and RCT were 31 (73.81%) and 35 (81.4%), respectively; the radiological success of them were 25 (59.52%) and 27 (62.79%). No statistically significant differences were found between the radiological and clinical successes of two groups at six months and 12 months ($p=0.093$, 0.221 , 0.456 , and 0.271 , respectively).

Conclusion: LSTR-bioceramic can be used as an effective treatment for deciduous molars with chronic periapical periodontitis and pulp necrosis.

Keywords: Abscess, Necrotic pulp, Pulp chamber, Sodium hypochlorite

INTRODUCTION

In modern dentistry, RCT for deciduous molars with chronic periapical periodontitis and pulp necrosis is common [1]; however, many children and their parents view it negatively due to its complexity, lengthy treatment process, high costs and the need for children's cooperation [2]. Therefore, paediatric dental researchers have been exploring more efficient and child-friendly alternative treatment methods.

In recent years, lateral condensation technique with a single-visit treatment regime (LSTR) has shown broad treatment prospects in the field of dentistry [3]. LSTR is a concept that includes several biological approaches in the treatment of carious lesions, especially in chronic periapical periodontitis with pulp necrosis, using a mixture of three antibiotics: metronidazole, ciprofloxacin, and minocycline [4]. Its core is the continuous sterilisation of the pulp chamber, root canal and periapex by antibiotics, thereby promoting tissue self-repair. Additionally, its unique feature is the elimination of the need for root canal preparation instruments, significantly simplifying the treatment procedure and enhancing the comfort of paediatric patients [5].

Bioceramic materials are recognised as excellent materials in modern dentistry. They are widely used in indirect pulp capping, direct pulp capping, pulpotomy, RCT, revascularisation and apical barrier techniques, and they have high treatment effectiveness

and success rates [6-11]. Bioceramic materials exhibit good biocompatibility, sealing ability, antibacterial properties, and stable chemical and mechanical properties [12]. In most dental procedures, these materials directly contact the dental pulp, forming a dentin bridge to protect the pulp [13]. Furthermore, they promote the proliferation of pulp cells while upregulating the expression of neural and mineralisation-related genes in dental pulp stem cells, inducing them to differentiate into various tissues such as dental pulp and dentin, ultimately facilitating the repair and regeneration of pulp tissue [14].

In the previous research, the authors explored bioceramic materials as a treatment option for vital inflamed pulp therapy in deciduous teeth and concluded that these materials demonstrate effective performance in treating vital inflamed pulp in deciduous molars affected by periapical periodontitis [15]. Consequently, bioceramic materials hold significant research value in both dental clinical settings and scientific research. This innovative treatment approach has the potential to reduce medical costs and treatment duration, decrease technical sensitivity, and significantly enhance the overall treatment experience for paediatric patients, thereby improving safety. It presents several advantages over traditional RCT. As there have been no prior reports regarding the application of bioceramic materials in LSTR therapy, the present study further substantiates the notion that LSTR employing bioceramic materials can serve as a second-line alternative to both RCT and LSTR with a mixture of antibiotics.

Therefore, the present study was conducted to clinically assess the efficacy of LSTR utilising bioceramic materials in the treatment of deciduous molars affected by chronic periapical periodontitis and pulp necrosis. The objective was to identify a superior treatment option compared to the current protocols that involve LSTR therapy by triple antibiotic paste and RCT.

MATERIALS AND METHODS

A randomised controlled trial was conducted in the Stomatological Healthcare Center, Shenzhen Maternity and Child Healthcare Hospital affiliated to Southern Medical University in Shenzhen, Guangdong, China, from January 2022 to December 2023. The experimental procedures were in accordance with the Declaration of Helsinki and were approved by the ethics committee of the Research Ethics Committee of Shenzhen Maternity and Child Healthcare Hospital (ethics No. SFYLS (2022) 049). The parents of children participating in the experiment understood the procedure and signed the informed consent.

Inclusion criteria:

- Children aged 3-8 years (under 8 years);
- Able to communicate normally with the dentist or nurse;
- Have eaten food within the last two hours before treatment;
- Deciduous molars must be fully erupted;
- Presenting with deep caries or failed pulpotomy;
- Clinical features indicating occlusion pain, pain on percussion, sinus opening, or abscess;
- Radiological features showing bifurcation, periapical radiolucency, and root resorption of less than one-third;
- No pain during probing of the root canal or root canal preparation;
- Parents who provided consent for participation in the study.

Exclusion criteria:

- Parents who refuse to allow participation in the experiment;
- Children who are unable to cooperate;
- Children with temporary or long-term systemic diseases;
- Those wearing orthodontic appliances;
- Deciduous molars that are not fully erupted;
- Healthy molars;
- Clinical features indicating abnormal mobility;
- Radiological features showing root resorption of more than one-third;
- Presence of pain during probing of the root canal preparation;
- If the child expresses pain during probing of the orifices of the root canals and root canal preparation, continue with treatment, but were excluded inclusion in the present study.

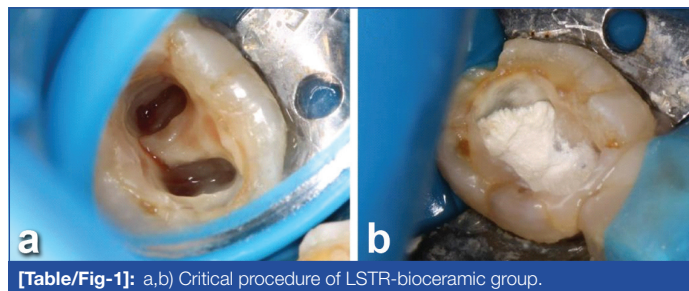
Sample size calculation: The sample size calculation was performed using the Open Epi program, version 3.01 (Andrew G. Dean and Kevin M. Sullivan, www.OpenEpi.com), in which the following criteria were used: success rate of 63% for the Zinc Oxide Eugenol (ZOE) paste and 93% for the Chloramphenicol, Tetracycline, Zinc oxide and eugenol (CTZ) paste, test power of 80% and significance level of 5%. The initial sample size was determined as 36 teeth per group. To minimise possible loss, a 20% increase was added, resulting in a final sample of 88 teeth (44 teeth per group) [5].

Study Procedure

Children were first diagnosed with chronic periapical periodontitis through inquiry, clinical examination and radiological examination, and they were then randomly divided into two groups.

Procedure of LSTR-bioceramic group: The treatment was carried out by a single operator. For the clinical procedure of the LSTR-

bioceramic group, access to the pulp chamber, exposure of all orifices of the root canals, and removal of the necrotic pulp tissue in the pulp chamber were gained using a ball bur (MANI Hanoi, Japan) with a high-speed handpiece (NSK, Japan). The chamber was then irrigated with a large amount of 3% sodium hypochlorite (NaOCl, Zhongding Co., Ltd., China) to disinfect and eliminate any remaining debris [Table/Fig-1a]. If a haemorrhage occurred, it was controlled by applying sterile cotton pellets moistened with 3% NaOCl against the pulp stumps for one minute. The cavity was then dried using cotton pellets. The iRootBP Plus (Innovative Bioceramic, Canada) was applied to the orifices of the root canals and the pulpal floor [Table/Fig-1b]. This was followed by the placement of glass-ionomer cement (Shofu, Japan) over the iRootBP Plus to seal the area. Immediately after, the teeth were restored with light-curing composite resin (Shofu, Japan; 3M ESPE, USA).



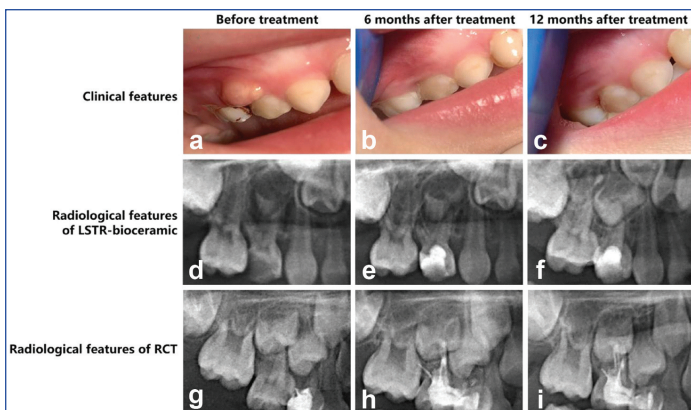
[Table/Fig-1]: a,b) Critical procedure of LSTR-bioceramic group.

For the RCT group procedure, the treatment was performed by the same operator who worked with the LSTR-bioceramic group. Access to the pulp chamber, exposure of all orifices of the root canals, and removal of the necrotic pulp tissue in the pulp chamber was gained using a ball bur with a high-speed handpiece. The root length was ascertained through diagnostic radiographs, which guided the treatment process. A rubber stop was affixed to a size 15 K-file (MANI HANOI, Japan) to ensure files were approximately 2 mm short of the radiographic apex. The canal was progressively enlarged utilising the M3 system (Yirui, China), incrementally advancing to a size 30. Extensive irrigation with 3% sodium hypochlorite (NaOCl) was conducted between instrument changes to improve debris removal. Afterwards, the canals were dried using sterile paper points. Vitapex (Vitapex, Japan) was then directly delivered into the canals using a prefilled syringe. Finally, glass-ionomer cement was applied over the Vitapex to seal the chamber, and the teeth were restored with light-curing composite resin.

Clinical and radiological evaluation after treatment, evaluations were conducted 6 months and 12 months after treatment to assess the treatment outcomes [Table/Fig-2]. Another operator performed these evaluations to ensure objectivity and minimise bias. Clinical success was defined as the complete absence of occlusal pain/pain to percussion, sinus opening/abscess and abnormal mobility. Clinical success is shown in [Table/Fig-2a-c]. Radiological success was defined as the complete absence of bifurcation/periapical radiolucency, increased root resorption and permanent tooth embryo incline. The radiological success of LSTR-bioceramic and RCT is shown in [Table/Fig-2d-i]. Extraction was conducted when permanent tooth embryo incline occurred. Cases of extraction were classified as clinical and radiological failed in the next evaluation.

STATISTICAL ANALYSIS

The WPS Office (12.1.0.15398, WPS Beijing, China) was used for the statistical analysis. The data were expressed as mean±Standard Deviation (SD), n, or %. Unpaired two-tailed Student's t-test was employed for age, and Chi-square test was employed for sex at baseline. A Z-test was employed for the success rates of the two groups at 6 months and 12 months. A p-value of less than 0.05 was considered statistically significant.



[Table/Fig-2]: Clinical and radiological success: a-c) Clinical features (54#); d-f) Radiological features of LSTR-bioceramic (54#); g-i) Radiological features of RCT (55#).

RESULTS

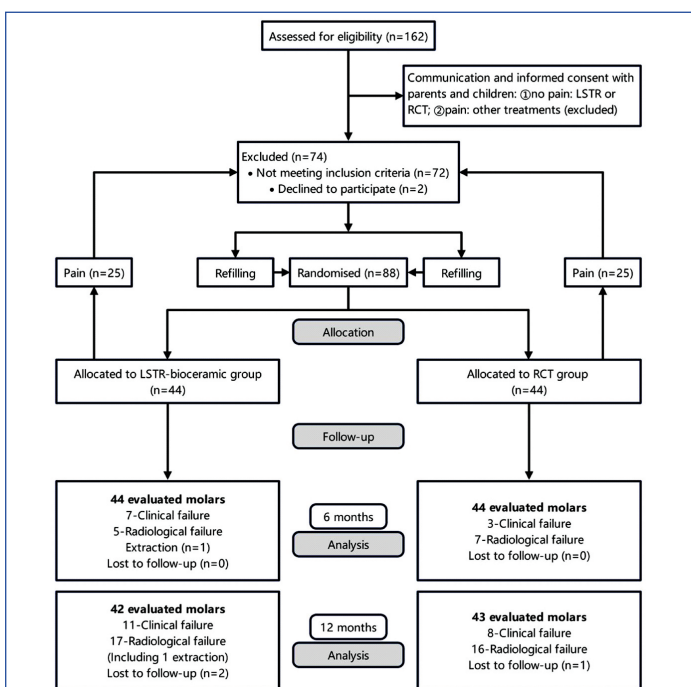
The distribution of tooth type is shown in [Table/Fig-3]. There was no significant difference in the age and sex of the two groups in the experiments at baseline (p-value >0.05) [Table/Fig-4]. A (Consolidated Standards of Reporting Trials) CONSORT flowchart of the present study is shown in [Table/Fig-5].

Tooth type	LSTR-bioceramic (n=44)	RCT (n=44)
First molars, n		
Upper (54/64#)	14	11
Lower (74/84#)	15	17
Second molars, n		
Upper (55/65#)	5	9
Lower (75/85#)	10	7

[Table/Fig-3]: Distribution of two groups by tooth type (N=88).

	LSTR-bioceramic (n=44)	RCT (n=44)	t-value	p-value
Age (years) (Mean±SD)	5.61±0.76	5.57±0.68	0.220	0.825
Gender (n)				
Male	20	21	0.046	>0.05
Female	24	23		

[Table/Fig-4]: Comparison of basic information between two groups (N=88). *Unpaired two-tailed Student's t-test for age, Chi-square test for gender; The p-value <0.05 was statistically significant



[Table/Fig-5]: Consolidated Standards of Reporting Trials (CONSORT) flowchart.

Comparison of clinical features in six months between two groups: At the follow-up examination at six months, in the LSTR-bioceramic group, one case reported occlusion pain/pain to percussion, and seven cases showed sinus opening/abscess (one case had both occlusion pain/pain to percussion and sinus opening/abscess). All cases had no abnormal mobility [Table/Fig-6], so the clinical success rate of the LSTR-bioceramic group was 37 (84.09%) [Table/Fig-7].

Parameters	6 months		12 months	
	LSTR-bioceramic (44)	RCT (44)	LSTR-bioceramic (42)	RCT (43)
Clinical features				
Occlusion pain/pain to percussion	1	0	4	2
Sinus opening/abscess	7	3	10	8
Abnormal mobility	0	0	8	2
Radiological features				
Bifurcation/periapical radiolucency	5	7	16	16
Increased root resorption	1	0	15	13
Permanent tooth embryo incline	1	0	7	3

[Table/Fig-6]: Clinical and radiological features of two groups after treatment at six and 12 months.

Results	Months	n (%)		p-value
		LSTR-bioceramic	RCT	
Clinical success	6	37/44 (84.09%)	41/44 (93.18%)	0.093
	12	31/42 (73.81%)	35/43 (81.40%)	0.221
Radiological success	6	39/44 (88.64%)	37/44 (84.09%)	0.456
	12	25/42 (59.52%)	27/43 (62.79%)	0.271

[Table/Fig-7]: Clinical and radiological success of two group after treatment at six and 12 months. *Z-test used; The p-value <0.05 was statistically significant

In the RCT group, there were no reports of occlusion pain or abnormal mobility, and the clinical success rate at six months was 93.18% (41 cases). Three cases had sinus openings/abscesses. Statistical analysis showed no significant difference in clinical success rates between the RCT and LSTR-bioceramic groups (p-value=0.093) [Table/Fig-6,7].

At six months, the LSTR-bioceramic group had a radiological success rate of 88.64% (39 cases), with five cases showing bifurcation/periapical radiolucency and one case of increased root resorption. In the RCT group, the radiological success rate was 84.09% (37 cases), with seven cases of bifurcation/periapical radiolucency but no increased root resorption [Table/Fig-6,7].

At 12 months, the LSTR-bioceramic group reported a clinical success rate of 73.81% (31 cases), with four cases of occlusion pain and 10 cases of sinus openings. The RCT group had a clinical success rate of 81.4% (35 cases). Again, no significant difference was found (p-value=0.221) [Table/Fig-6,7].

Radiologically, the LSTR-bioceramic group had a success rate of 59.52% (25 cases) with 16 cases of radiolucency, while the RCT group had a rate of 62.79% (27 cases) with no significant difference (p-value=0.271) [Table/Fig-6,7].

DISCUSSION

The LSTR represents a promising alternative to traditional endodontic treatment for deciduous molars with periapical periodontitis and chronic periapical periodontitis with pulp necrosis [16]. The key advantage of LSTR lies in its potential to reduce treatment costs, shorten treatment duration, decrease technique sensitivity and enhance the overall treatment experience for children. In contrast,

traditional endodontic treatment, RCT, although effective, often involves complex procedures and a longer recovery period [9,17].

As recent studies on RCT have progressed, many paediatric dentists have identified some unavoidable drawbacks associated with the procedure. In the present study region, the cost of RCT is approximately twice that of the less invasive technique known as LSTR. Furthermore, many parents hold a common misconception about RCT for primary (deciduous) teeth; they believe that the treatment will completely kill and remove the dental nerves, potentially affecting the eruption of permanent teeth. As a result, the acceptance of RCT for primary teeth has not been as smooth as anticipated [9,17].

Additionally, RCT requires the use of metal instruments, sharp tool shapes, and involves complex procedures that can cause psychological and physiological discomfort for children. Most children also report significant postoperative pain lasting almost a week after the procedure. This raises concerns, as RCT may not align with the principle of providing comfort in paediatric dentistry. In contrast, LSTR appears to offer more advantages than RCT. In our study, the treatment time for the LSTR-bioceramic group was shorter than that for the RCT group, and parents reported lower levels of postoperative pain in their children following LSTR treatment.

Although the authors have not yet recorded or statistically analysed specific data, the clinical experiences of paediatric dentists, parents and children suggest that LSTR has practical clinical benefits. In future studies, the authors planned to collect and objectively document the present study data [17,18].

The use of bioceramic materials in dentistry has been gaining momentum due to their unique properties [6]. They exhibit excellent biocompatibility, durability, sealing ability, the ability to promote tissue regeneration, and stable chemical and mechanical properties [12]. So, they are recognised as excellent materials in modern dentistry. In the latest cytological research, it was found that they can significantly promote the proliferation, cell adhesion and migration of deciduous dental pulp stem cells [19]. Furthermore, they could better upregulate the osteogenic-related gene expression and some autophagy pathways, to better promote the process of bone/tooth differentiation [20-22].

In the present study, the authors tried to utilise the advantage of bioceramic materials, after synthesising calcium hydroxide, bioceramic materials change the space inside the root canal to alkaline, creating a positive microenvironment that is beneficial for inhibiting bacterial growth. When the inflammation in the root canal is corrected, they induce stem cells derived from the bone to differentiate into osteogenesis at the periapex, leading to an increase in alveolar bone density at the affected periapex.

Currently, LSTR for the treatment of deciduous molar with chronic periapical periodontitis with pulp necrosis primarily relies on a range of drugs, including metronidazole, ciprofloxacin, minocycline, or other similar antibiotics, which are called 3Mix [4]. Deciduous teeth have many accessory canals, porosity and permeability in the chamber floor, indicating a probable connection between pulp and periodontal tissues. 3Mix can distribute through these regions and play a sustained sterilisation role [4].

However, many regions are unable to obtain the finished products of 3Mix through formal channels, and they also need to mix them by themselves, which may cause medical disputes among parents. In addition, the use of antibiotics for a long time might spread throughout the body and cause side-effects, such as drug resistance in bacteria [18,23]. So, bioceramic materials could be more convenient and safer to use as they have bactericidal effects and promote better bone tissue regeneration [23]. So, it is reasonable to study the effects of bioceramic materials in LSTR.

Moreover, there have been no previous reports on the use of bioceramic materials in LSTR therapy for chronic periapical

periodontitis with pulp necrosis in deciduous teeth. In the present study, the clinical and radiological success rates of the LSTR-bioceramic group and the RCT group were similar at 6 months and 12 months, and there was no statistical difference. The results above certified bioceramic materials have therapeutic effects; hence, in the context of LSTR, bioceramic materials play a crucial role in sterilising lesions and facilitating tissue repair.

However, the success rate of the LSTR-bioceramic group was lower than the rates reported in previous studies, using a mixture of three antibiotics, to some extent (10-16%) [4,5]. Castro M et al., reported a clinical success rate of 86.4% in LSTR with chloramphenicol, tetracycline, zinc oxide and eugenol at 36 months [5], while Nakornchai S et al., showed clinical success was 100% (6 and 12 months) with radiological success was 76% (12 months) in LSTR with metronidazole, ciprofloxacin, and minocycline [4].

It is worth noting that the success rates of most LSTR procedures were similar to or higher than that of RCT in these studies. From a naval perspective, the present study has a certain degree of research value. The present study introduces the observation of the permanent tooth embryos, a previously unexplored aspect in the literature. The function of deciduous teeth is not only to chew and promote the development of dentition but also to guide the eruption of permanent teeth [24]. In other words, although there exists inflammation at the periapex, as long as it does not affect the development of permanent tooth embryos, the control of inflammation might be acceptable.

In a study by Smith NL et al., the internal absorption of roots not affecting the permanent tooth embryos does not count as treatment failure [25]. Nakornchai S et al., chose to observe teeth displaying internal resorption instead of extracting these teeth as failures [4].

Limitation(s)

The present study has several limitations, including insufficient detection indicators that do not fully demonstrate the advantages of bioceramic materials. The indicators considered include operation time compared to LSTR with three antibiotics, dentist experience, potential allergic reactions to long-term antibiotics and changes in tooth colour. Some scholars argue that treatment success for chronic periapical periodontitis with pulp necrosis in deciduous teeth is more related to root condition than to the technology used. Although the present study sample size is larger than that of previous studies, it still includes many deciduous teeth with poor prognoses. Expanding the sample size may help address this issue. These limitations will inform the authors future research, and adding more detection indicators could better illustrate the benefits of bioceramic materials in treating chronic periapical periodontitis in deciduous molars.

CONCLUSION(S)

In the present study, the authors evaluated the outcomes of treatment 12 months post-intervention, focusing specifically on the incidence of periapical periodontitis affecting permanent tooth embryos. Remarkably, seven cases of this condition were identified, indicating a notable success in preventing complications. Among the treatment groups, the success rate of the LSTR bioceramic group was comparable to that of the traditional RCT group, signifying a potential breakthrough in treatment protocols. The present research explores a range of treatment options that address the unique needs of various regions, rather than simply replacing existing, well-established methods or materials. Through the present study exploration, the authors aimed to provide scholars and practitioners with broader perspectives and insights that could lead to improved outcomes in dental care.

REFERENCES

- [1] Yu Y, Zhou X, Zheng LW. Advanced research on root canal therapy for primary teeth. *Hua Xi Kou Qiang Yi Xue Za Zhi*. 2020;38(2):205-10.

- [2] Tzigkounakis V, Merglová V, Hecová H, Netolický J. Retrospective clinical study of 90 avulsed permanent teeth in 58 children. *Dent Traumatol.* 2008;24(6):598-602.
- [3] Almarji W, Laflouf M, Tolibah YA. Evaluation of the modified 3Mix-Simvastatin combination in non-instrumental endodontic therapy of necrotic primary molars: A two-arm randomized controlled trial. *Clin Exp Dent Res.* 2024;10(2):e860.
- [4] Nakornchai S, Banditsing P, Visetratana N. Clinical evaluation of 3Mix and Vitapex as treatment options for pulpally involved primary molars. *Int J Paediatr Dent.* 2010;20(3):214-21.
- [5] Castro M, Lima M, Lima C, Moura M, Moura J, Moura L. Lesion sterilization and tissue repair with chloramphenicol, tetracycline, zinc oxide/eugenol paste versus conventional pulpectomy: A 36-month randomized controlled trial. *Int J Paediatr Dent.* 2023;33(4):335-45.
- [6] Jitaru S, Hodisan I, Timis L, Lucian A, Bud M. The use of bio-ceramics in endodontics- literature review. *Clujul Med.* 2016;89(4):470-73. Doi: 10.15386/cjmed-612. Epub 2016 Oct 20. PMID: 27857514; PMCID: PMC5111485.
- [7] Morotomi T, Washio A, Kitamura C. Current and future options for dental pulp therapy. *Jpn Dent Sci Rev.* 2019;55(1):05-11.
- [8] Islam R, Islam MRR, Tanaka T, Alam MK, Ahmed HMA, Sano H. Direct pulp capping procedures - Evidence and practice. *Jpn Dent Sci Rev.* 2023;59:48-61.
- [9] Khandelwal A, Janani K, Teja K, Jose J, Battineni G, Riccitiello F, et al. Periapical healing following root canal treatment using different endodontic sealers: A systematic review. *Biomed Res Int.* 2022;2022:3569281.
- [10] Anna B, Craig D, Gordon L, Eric S. Current trends in regenerative endodontics: A web-based survey. *J Endod.* 2024;50(2):181-88.
- [11] Ayub K, Darcey J. Endodontic management strategies for permanent teeth with immature apices. *Prim Dent J.* 2023;12(1):35-42.
- [12] Rawat A, Geogi CC, Dubey S, Singh P. Bioceramics in endodontics - A review. *IP Indian J Conserv Endod.* 2022;7(4):163-71. Doi: 10.18231/ijce.2022.037.
- [13] Tawil PZ, Duggan DJ, Galicia JC. Mineral trioxide aggregate (MTA): Its history, composition, and clinical applications. *Compend Contin Educ Dent.* 2015;36(4):247-52.
- [14] Li XL, Fan W, Fan B. Dental pulp regeneration strategies: A review of status quo and recent advances. *Bioactive Materials.* 2024;38:258-75. ISSN 2452-199X. Doi: 10.1016/j.bioactmat.2024.04.031. Available at: <https://www.sciencedirect.com/science/article/pii/S2452199X24001622>.
- [15] Liu Y, Sun J. Clinical evaluation of vital inflamed pulp therapy as treatment options for deciduous molars with periapical periodontitis. *Int J Dent Med.* 2024;10(1):14-17.
- [16] Coll JA, Vargas K, Marghalani AA, Chen CY, AlShamali S, Dhar V, et al. A Systematic review and meta-analysis of nonvital pulp therapy for primary teeth. *Pediatr Dent.* 2020;42(4):256-461.
- [17] Achanta A, Reche A, Dakhale R, Bharate RR. A comprehensive review of lesion sterilization and tissue repair: An alternative for pulpectomy in deciduous teeth. *Cureus.* 2023;15(11):e48218.
- [18] Ahmad MZ, Sadaf D, Merdad KA, Almohaimeed A, Onakpoya IJ. Calcium hydroxide as an intracanal medication for postoperative pain during primary root canal therapy: A systematic review and meta-analysis with trial sequential analysis of randomised controlled trials. *J Evid Based Dent Pract.* 2022;22(1):101680.
- [19] Parisay I, Qeidari A, Sabouri E, Khorakian F, Bagheri H. Cytotoxicity and induced apoptosis of a new bioceramic cement containing simvastatin on stem cells from human exfoliated deciduous teeth. *Dent Res J (Isfahan).* 2022;19:79.
- [20] Sanz JL, Forner L, Almudéver A, Guerrero-Gironés J, Llena C. Viability and stimulation of human stem cells from the apical papilla (hSCAPs) induced by silicate-based materials for their potential use in regenerative endodontics: A systematic review. *Materials (Basel).* 2020;13(4):974.
- [21] Shi H, Zhou K, Wang M, Wang N, Song Y, Xiong W, et al. Integrating physico-mechanical and biological strategies for BTE: Biomaterials-induced osteogenic differentiation of MSCs. *Theranostics.* 2023;13(10):3245-75.
- [22] Cheng S, Zhao C, Liu S, Chen B, Chen H, Luo X, et al. Injectable self-setting ternary calcium-based bone cement promotes bone repair. *ACS Omega.* 2023;8(19):16809-23.
- [23] Wang Z, Shen Y, Haapasalo M. Antimicrobial and antibiofilm properties of bioceramic materials in endodontics. *Materials (Basel).* 2021;14(24):7594. Doi: 10.3390/ma14247594.
- [24] Aruede G, Pepper T. Anatomy, Permanent Dentition. 2023 May 22. In: StatPearls [Internet]. Treasure Island (FL): StatPearls Publishing; 2024 Jan.
- [25] Smith NL, Seale NS, Nunn ME. Ferric sulfate pulpotomy in primary molars: A retrospective study. *Pediatr Dent.* 2000;22(3):192-99.

PARTICULARS OF CONTRIBUTORS:

1. Attending Physician, Dental Home Department and Department of Endodontics, Shenzhen Stomatology Hospital, Shenzhen, Guangdong, China.
2. Attending Physician, Dental Home Department and Department of Endodontics, Shenzhen Stomatology Hospital, Shenzhen, Guangdong, China.
3. Director, Dental Home Department and Medical Affairs Department, Shenzhen Stomatology Hospital, Shenzhen, Guangdong, China.
4. Director, Stomatological Healthcare Centre, Shenzhen Maternity and Child Healthcare Hospital affiliated to Southern Medical University, Shenzhen, Guangdong, China.
5. Director, Stomatological Healthcare Centre, Shenzhen Maternity and Child Healthcare Hospital affiliated to Southern Medical University, Shenzhen, Guangdong, China.

NAME, ADDRESS, E-MAIL ID OF THE CORRESPONDING AUTHOR:

Yun Liu,
Fuqiang Road 3012, Shenzhen, Guangdong, China.
E-mail: 158046828@qq.com

PLAGIARISM CHECKING METHODS: (Lain H et al.)

- Plagiarism X-checker: Sep 26, 2024
- Manual Googling: Jan 04, 2025
- iThenticate Software: Jan 06, 2025 (11%)

ETYMOLOGY: Author Origin

EMENDATIONS: 6

AUTHOR DECLARATION:

- Financial or Other Competing Interests: None
- Was Ethics Committee Approval obtained for this study? Yes
- Was informed consent obtained from the subjects involved in the study? Yes
- For any images presented appropriate consent has been obtained from the subjects. Yes

Date of Submission: **Sep 21, 2024**

Date of Peer Review: **Oct 16, 2024**

Date of Acceptance: **Jan 08, 2025**

Date of Publishing: **Mar 01, 2025**